


Plaque Rupture at Left Main during Angiography

**Xiaofan Wu Hong Liu
Shuzheng Lv**

**Beijing Anzhen Hospital
Capital Medical University**

Disclosure Statement of Financial Interest

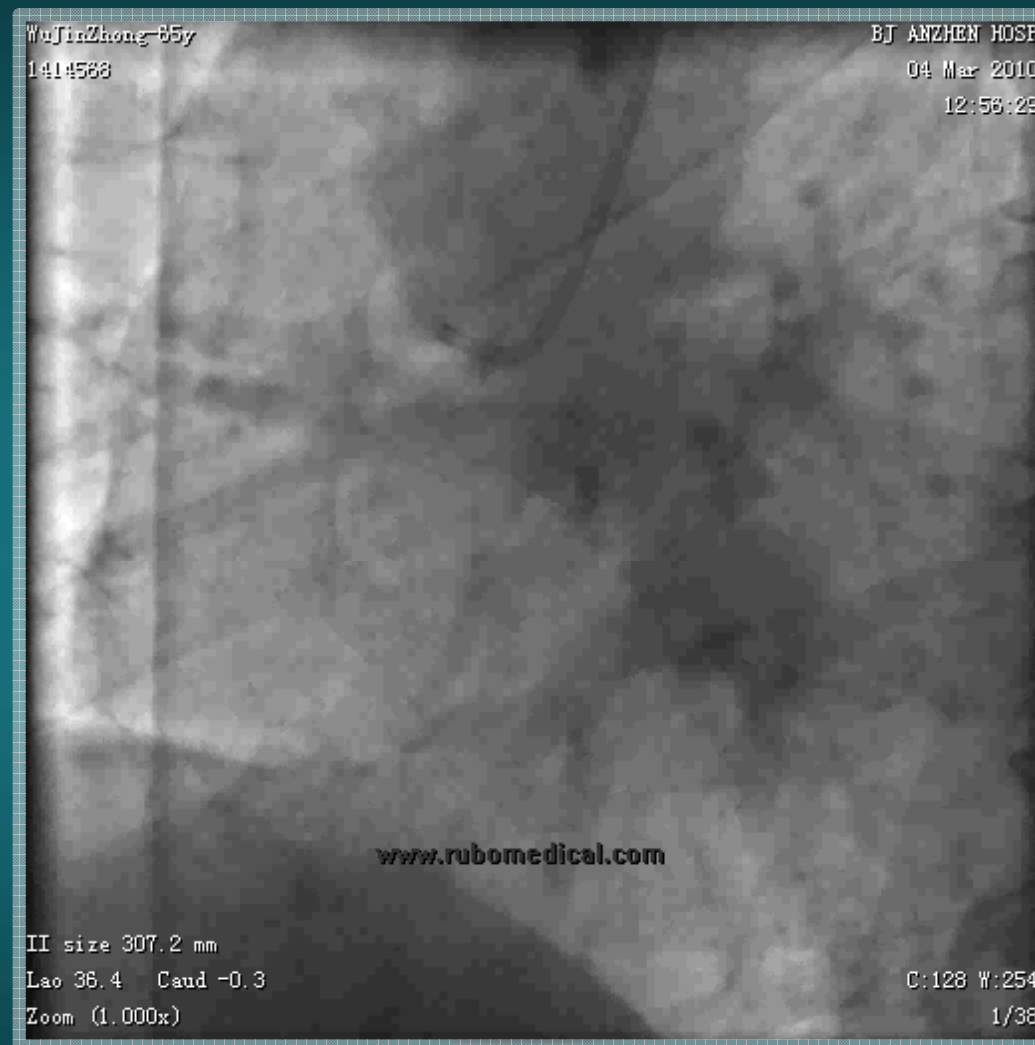I DO NOT have a financial interest/arrangement or affiliation with one or more organizations that could be perceived as a real or apparent conflict of interest in the context of the subject of this presentation



Clinical Presentation

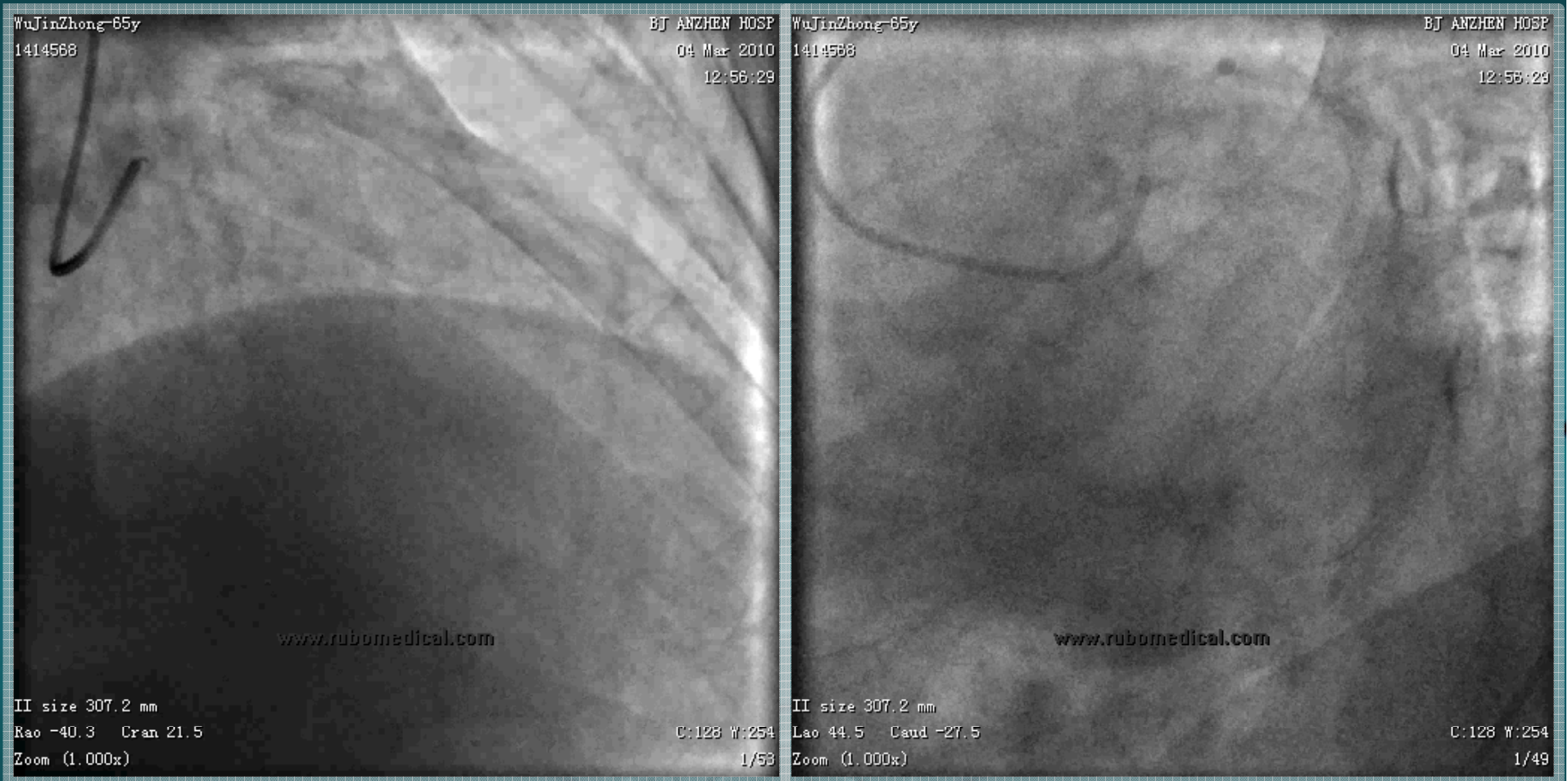
- 65-year-old male
- AMI (anterior) 28 days ago in local hospital
- No reperfusion by using of fibrinolytic or PCI
- Risk factors: Hypertension, DM

Baseline Angiogram



Stenosis at disRCA

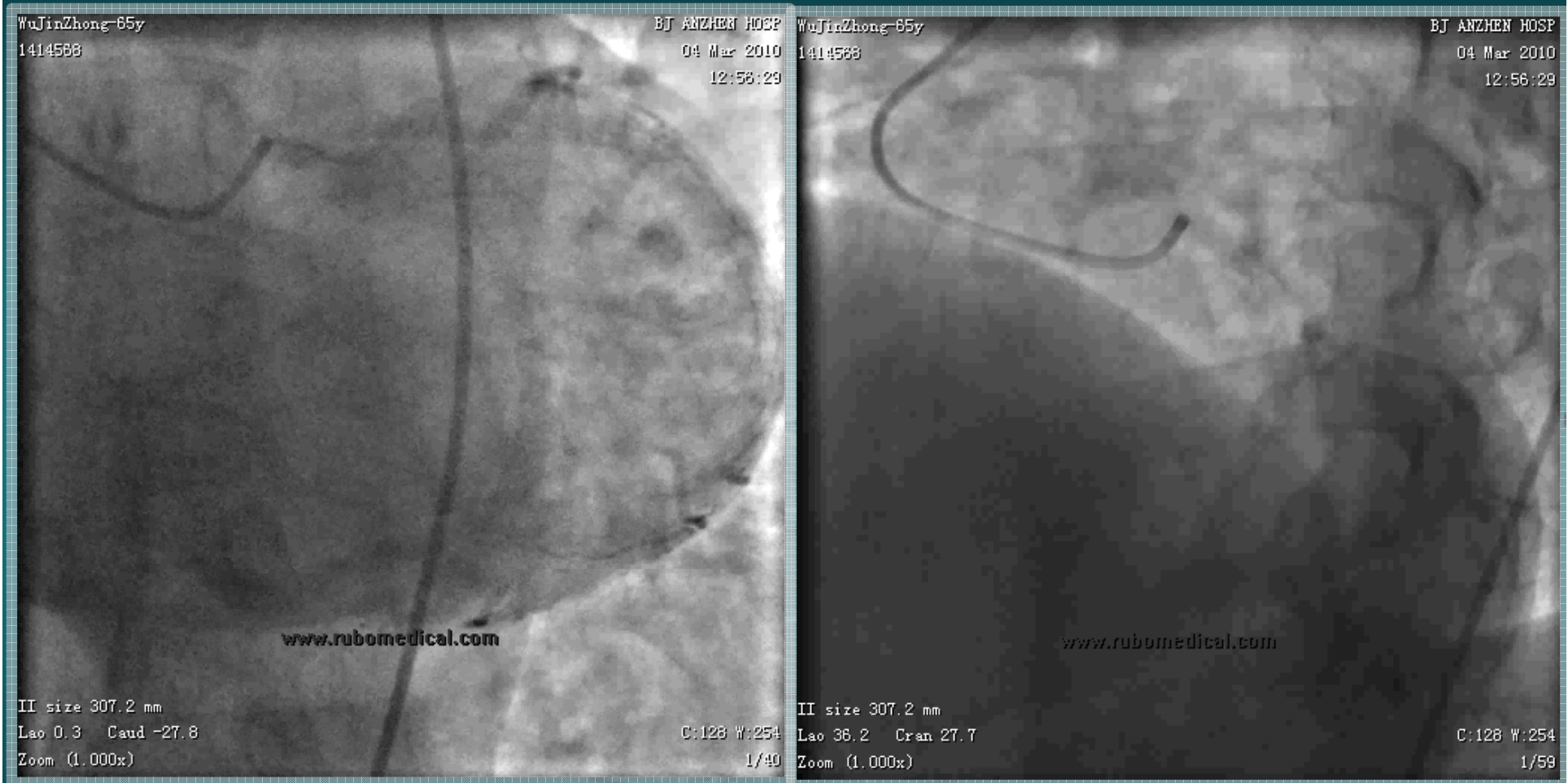Baseline Angiogram



Stenosis at pLAD-D & Ramus

Beijing Anzhen

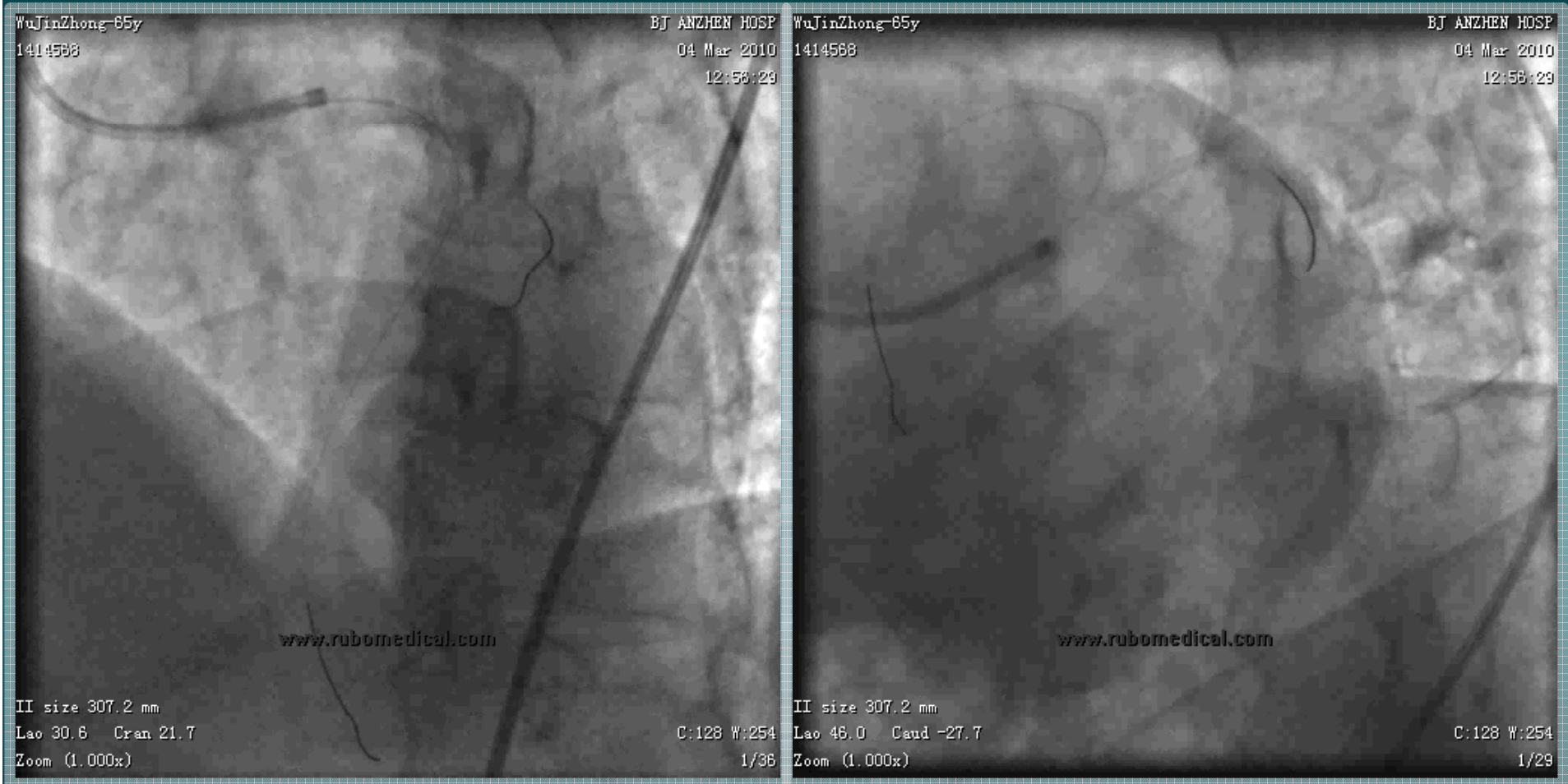
Baseline Angiogram



Circular masses flush from LM to LAD

Beijing Anzhen

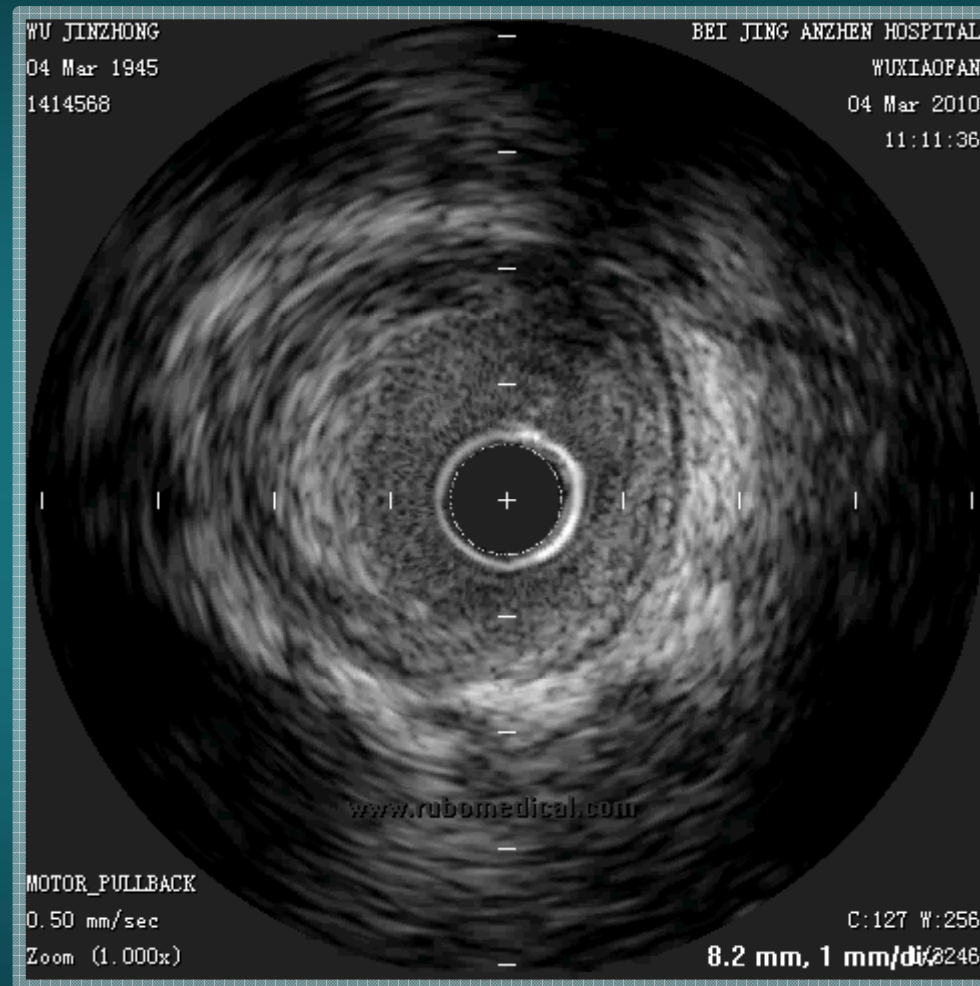Coronary intervention



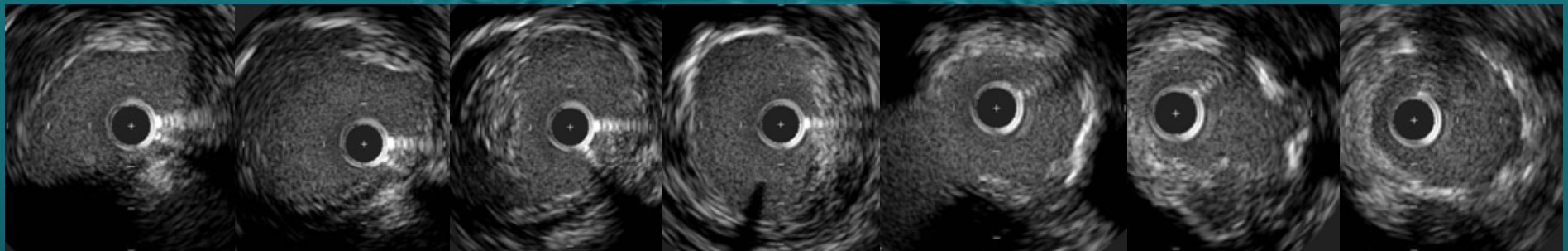
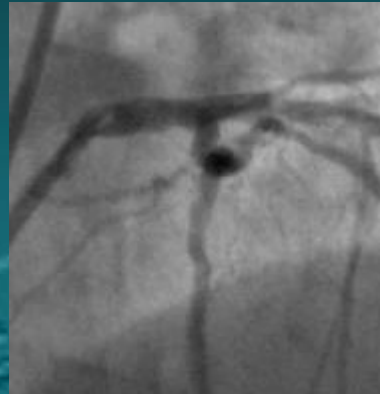**Provisional Lepu 3.5*24mm (16atm) at LAD,
Excel 2.5*24mm (12atm) at Ramus**

Beijing Anzhen

Baseline IVUS at LAD-LM



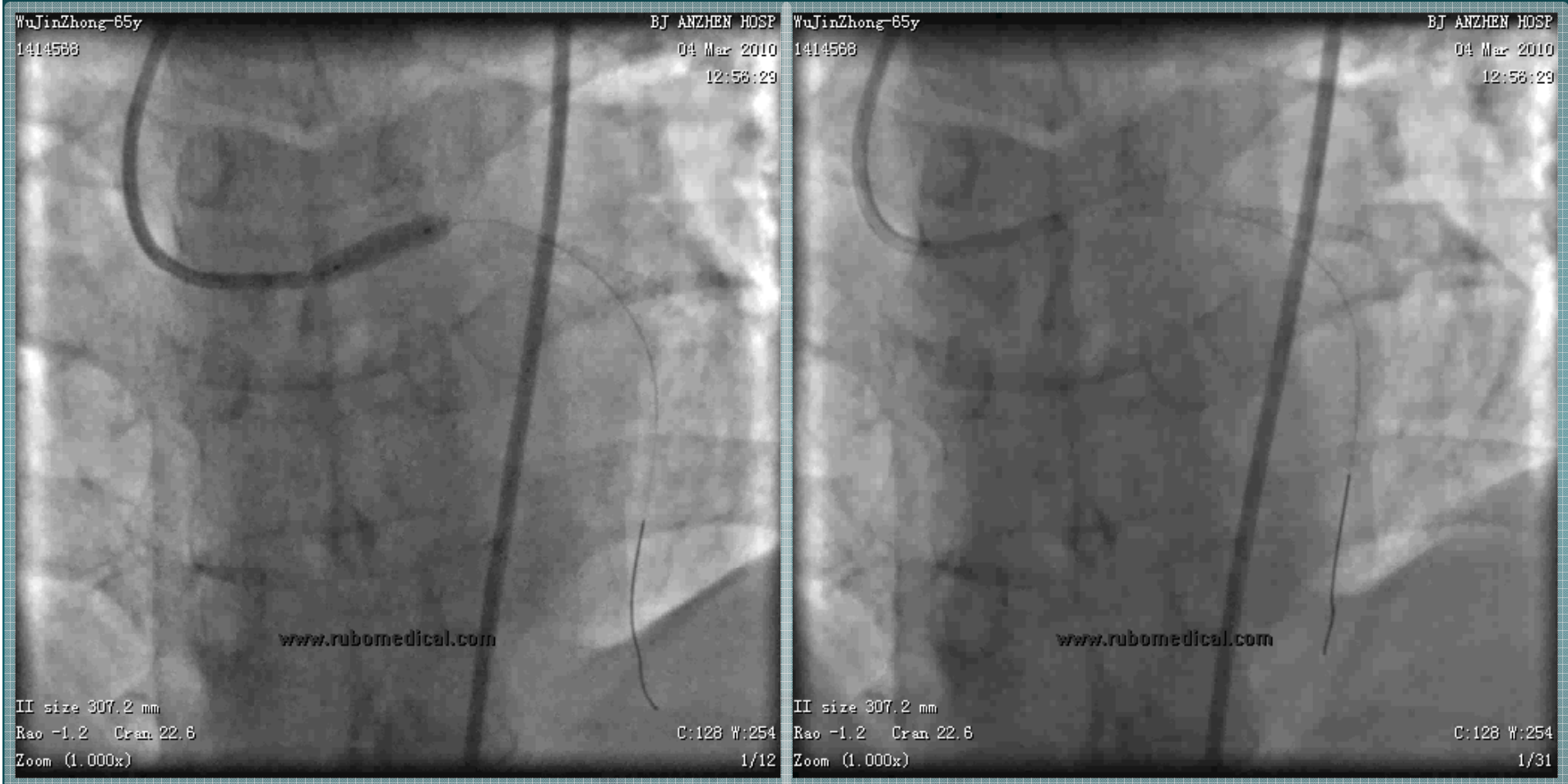
Baseline IVUS at LAD-LM



LA: 7.4 mm²
EEM: 24.6 mm²

LA: 6.2 mm²
EEM: 20.4 mm²

Coronary intervention



Lepu 4.0*12mm (18atm) at LM ostium

Beijing Anzhen

Post-PCI IVUS at LAD-LM

